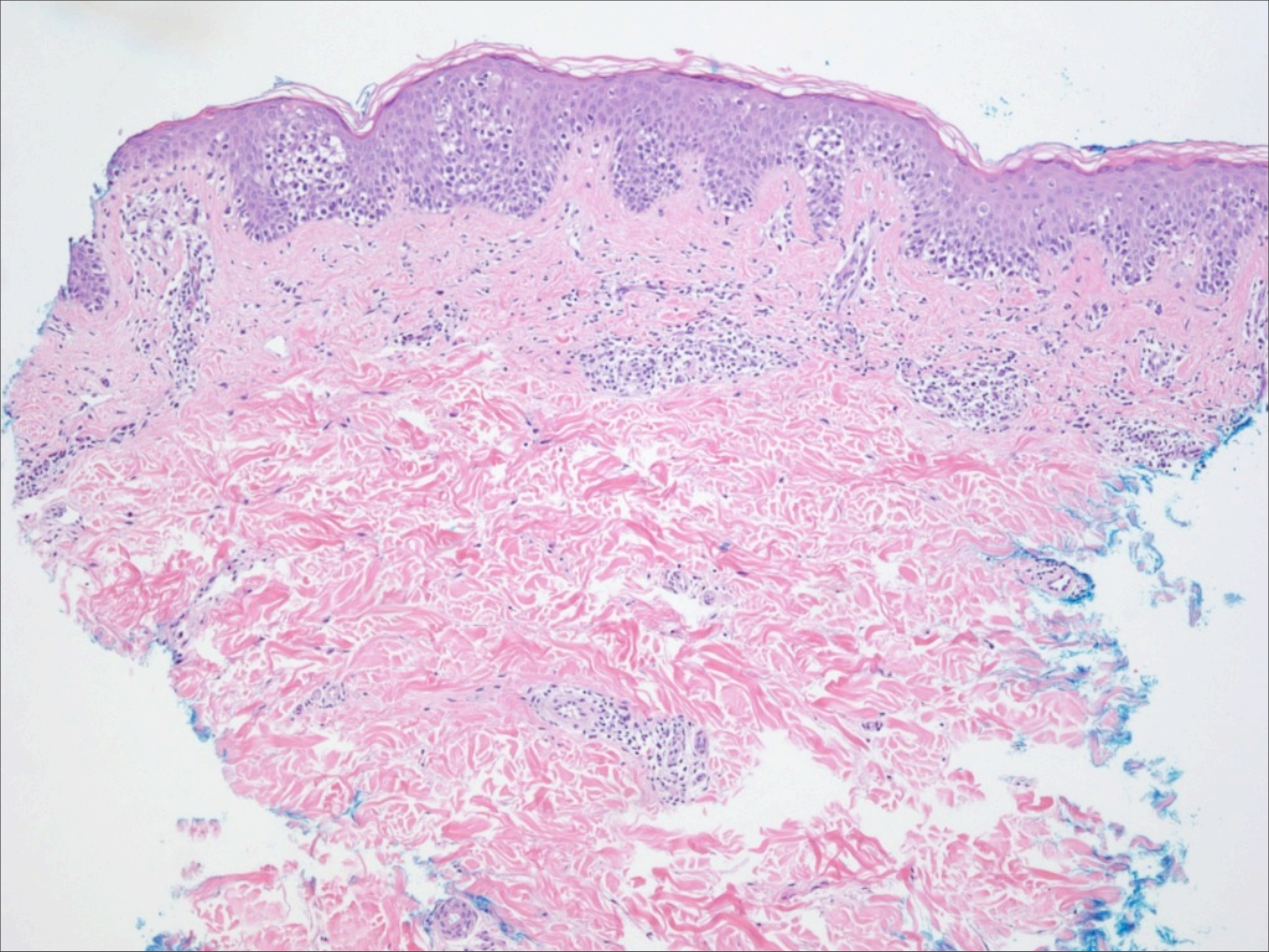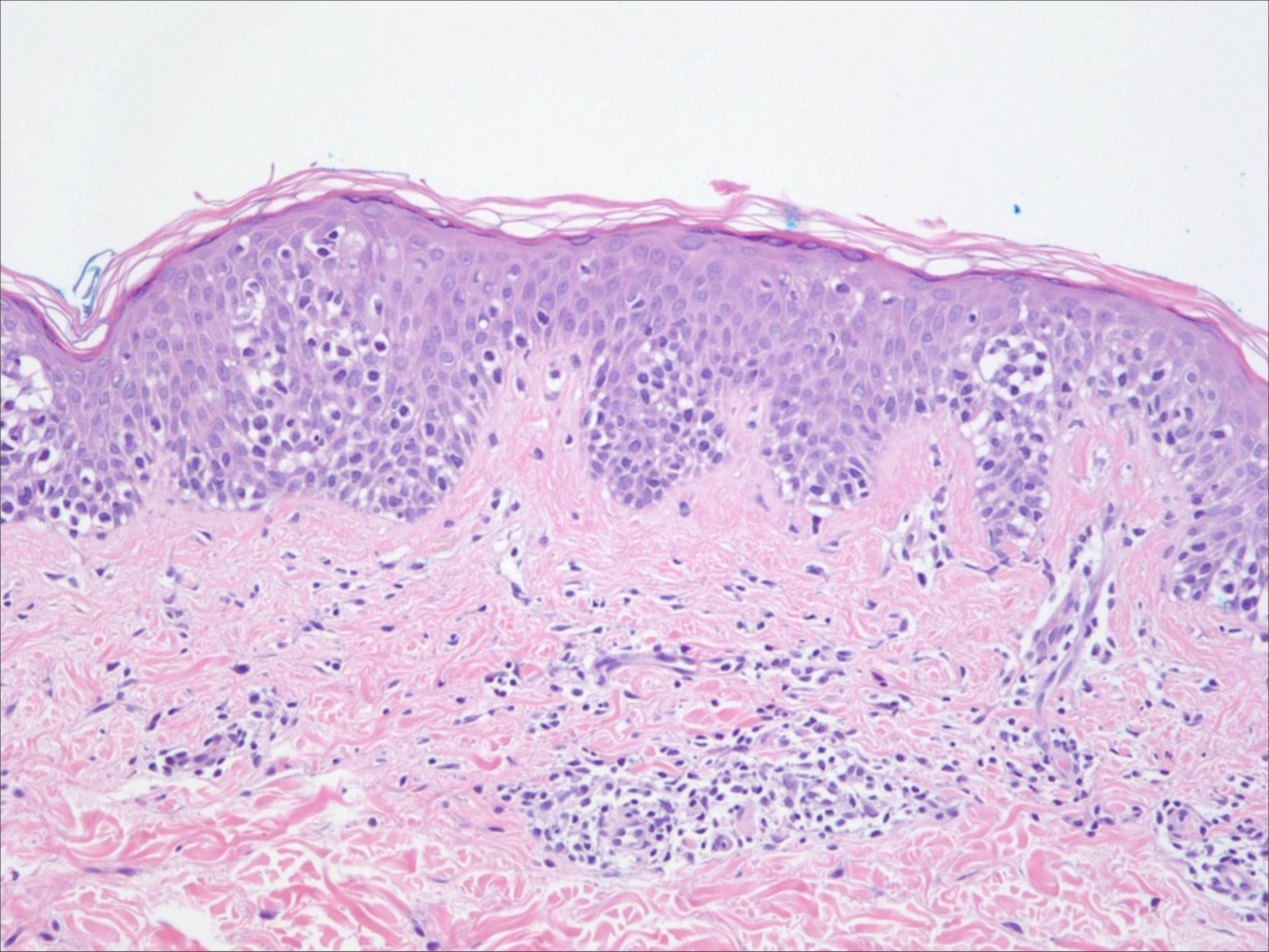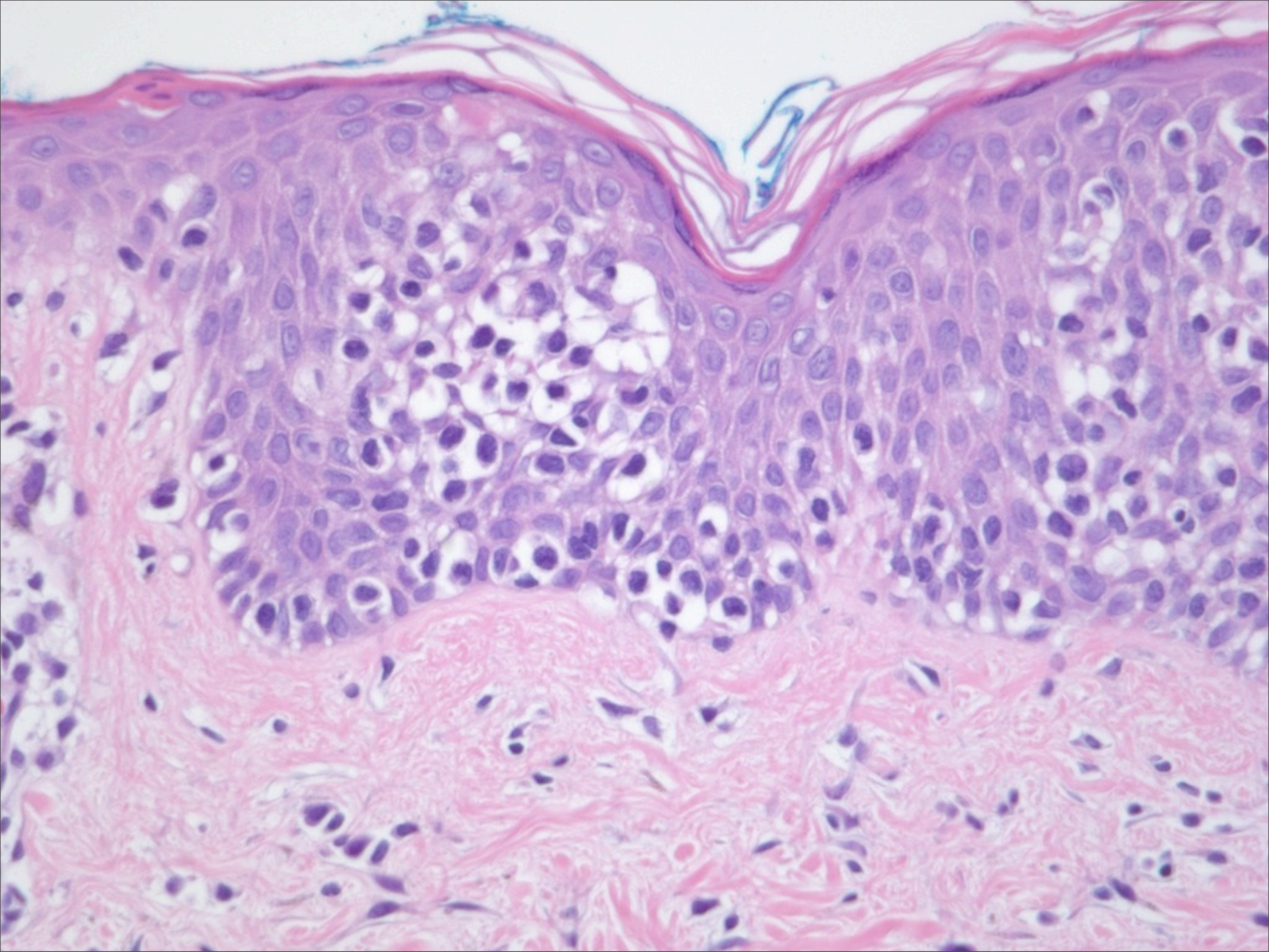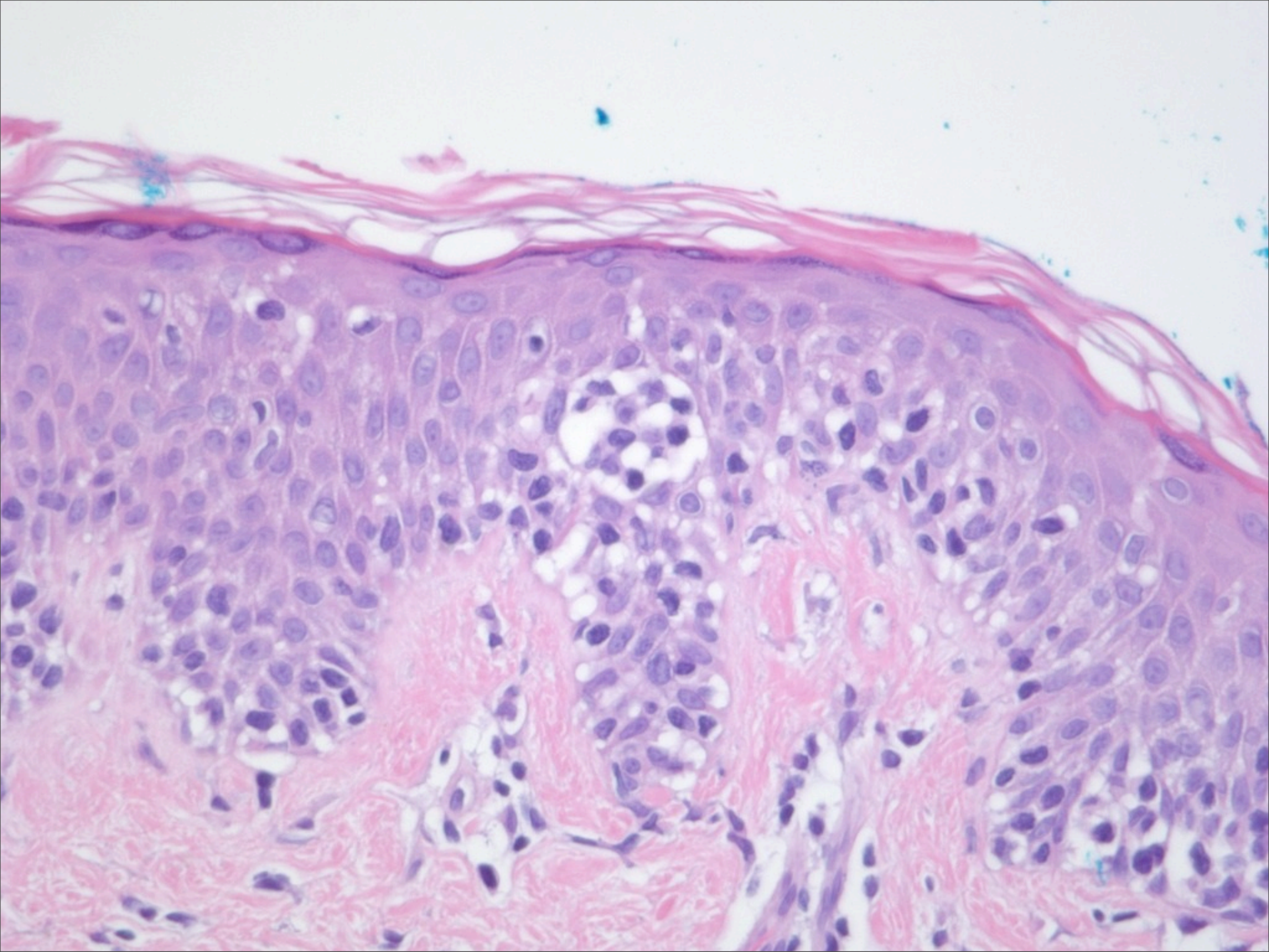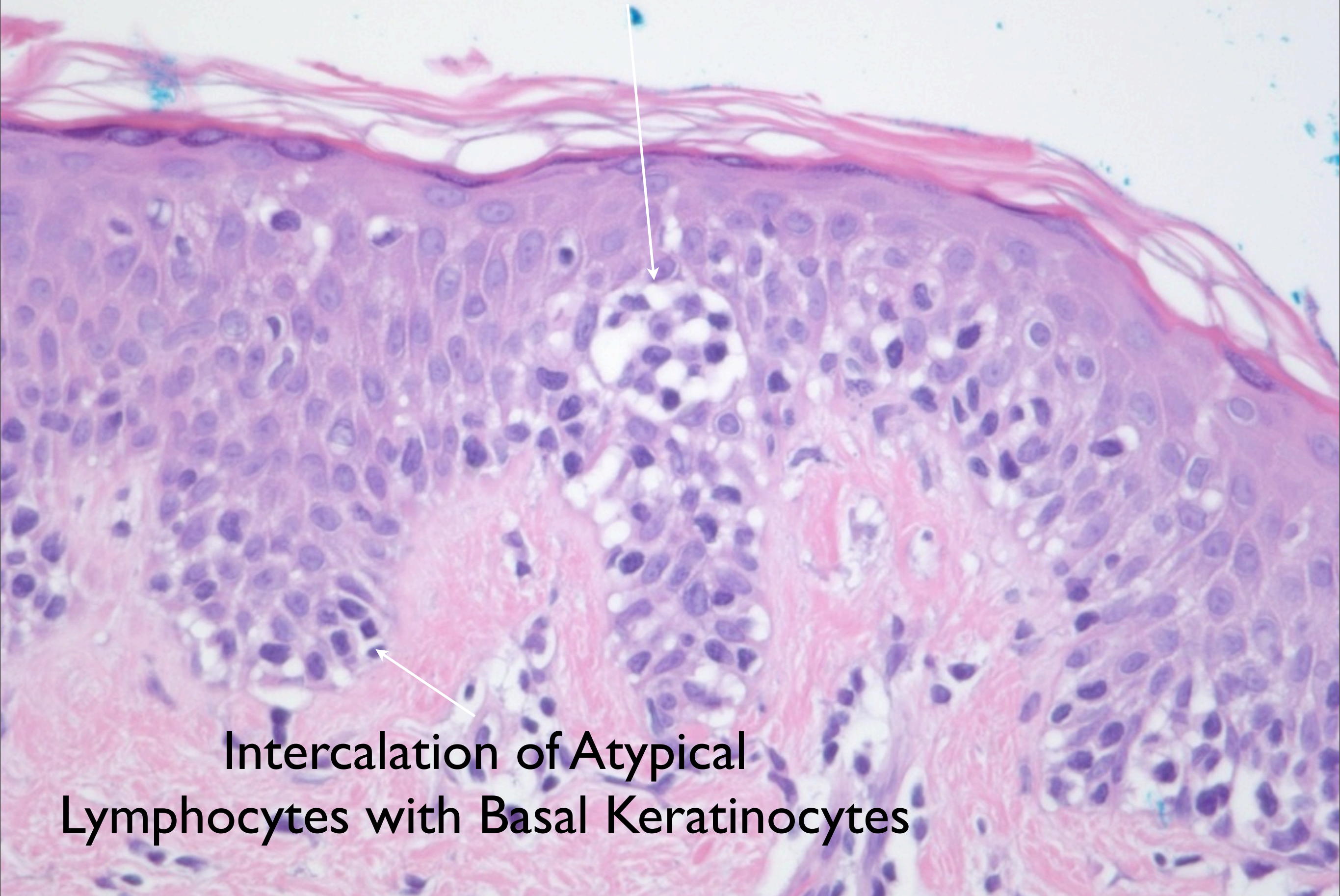


Mycosis Fungoides

Pautrier Microabscess



Intercalation of Atypical
Lymphocytes with Basal Keratinocytes